

Fracture fixation of distal part of the radius: A comparative study of different methods

William .A. Isapure*

Consultant, Bharati Vidhyapeeth Medical Collage & Hospital, Sangli, India & Isapure Orthopaedic Hospital and Trauma Center, Miraj, India.

***Corresponding author:** Dr. William A. Isapure, Consultant, Dept. of Orthopaedics, Bharati Vidhyapeeth Deemed University, Sangli, Maharashtra, India. ; **Email:** anuanish@hotmail.com

Abstract

Background: A variety of treatment modalities are available for fracture of distal radius. However, there is a lack of consensus on the preferred treatment in these cases.

Objective: To compare the different methods for the treatment fracture of distal part of the radius based on the outcome at the end of treatment.

Methods: Analysis of cases with fracture of distal radius treated at our centre over a period of seven years. A total of 301 patients were included in the study and end of treatment outcome was compared based on clinical appearance of the wrist at discharge, restoration of normal movements of the wrist joint and resumption of normal activities.

Results: Of the total number of cases admitted for fracture distal radius, nearly 75% cases were operated on using Percutaneous Fixation with K-wires (n=80), Locking Compression Plate (n=75), and External Fixation (n=77). It was observed that the clinical appearance of the wrist joint was remarkably better in patients treated with Locking Compression Plate (93.3%) than Percutaneous Fixation with K-wires and External Fixation. Better treatment outcome with regard to the restoration of movements of the wrist joint and resumption of normal activities was noted for patients treated with Locking Compression Plate (96%) than Percutaneous Fixation with K-wires and External Fixation.

Conclusions: Our study concludes that Locking Compression plate is a better treatment option for fracture of distal radius than the percutaneous fixation, and external fixation methods.

Keywords: Distal radius fracture, K-wires, Locking Compression Plate, External Fixation

Introduction

Fracture of the distal radius is a common injury of the upper extremity. Fractures of distal radius usually occur as a result of high-energy trauma in younger individuals [1]. Besides, these fractures are also reported in elderly osteoporotic patients [2]. A variety of treatment modalities are available for management of fracture of distal radius. The fracture of the distal radius can be treated conservatively

using a plaster cast or by methods such as external fixation, percutaneous fixation with K-wires or Locking Compression Plate (LCP). The primary goal of treatment in fractures of distal radius is to obtain anatomical reduction and stable fixation so as to minimize the risk of post-traumatic arthritis [1]. Though a variety of treatment options are available for treatment of fracture distal radius, there is a lack of consensus on the preferred treatment modality that

needs to be followed. There is not enough evidence in the published literature to suggest or recommend any specific treatment for distal radius fractures [3,4]. The present study was conducted with an aim to compare the effectiveness of different treatment modalities for management of fracture of distal part of the radius based on the treatment outcome.

Materials and Methods

Material of the study consisted of all the patients admitted to our centre for treatment of fracture distal end of radius. The study was conducted over a period of 7 years and detailed analysis of cases with fracture of distal radius treated at our centre was carried out. A total of 301 patients were included in the study and end of treatment outcome was compared based on clinical appearance of the wrist at discharge, restoration of normal movements of the wrist joint and resumption of normal activities. The details were entered in a data sheet and analysed and the results obtained are shown in proportions

Results

Over a period of 7 years, a total of 301 patients were treated for fracture distal radius. Of the total number of cases admitted for fracture distal radius, 24% cases were treated conservatively (Figure 1) while the others (76%) were treated using Percutaneous Fixation with K-wires (n=80), Locking Compression Plate (n=75), and External Fixation (n=77). Different procedures were performed on a similar number of cases in each group. Details of procedures performed on patients treated for the fracture of distal radius over the study period are shown in Table 1.

Better treatment outcome with regard to the restoration of movements of the wrist joint and resumption of normal activities was noted for patients treated with Locking Compression Plate (96%) than Percutaneous Fixation with K-wires (56.3%) and External Fixation (32.5%).

Table 1: Treatment details of the patients treated for fracture of distal radius over the study period

Year	Percutaneous Fixation with K-wires	Locking Compression Plate (LCP)	External Fixation	Total Operated Patients
2005	5	7	6	18
2006	8	9	13	30
2007	6	9	5	20
2008	11	12	21	44
2009	6	10	4	20
2010	15	11	4	30
2011	6	14	13	33
2012	23	3	17	37
Total	80	75	77	232

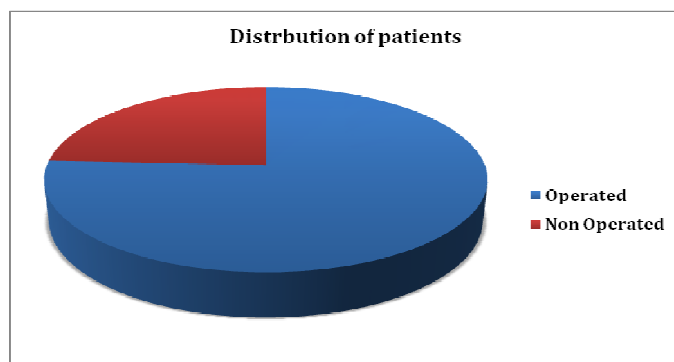
Table 2: Clinical appearance of the wrist joint after treatment

Procedure	Number of patients	Better restoration and wrist appearance	Poor restoration and wrist appearance
Locking Compression Plate (LCP)	75 (100%)	70 (93.3%)	5 (6.7%)
Percutaneous Fixation with K-wires	80 (100%)	52 (65%)	28 (35%)
External Fixation	77 (100%)	47 (61%)	30 (39%)

Table 3: Restoration of movements of the wrist joint and resumption of normal activities

Procedure	Number of patients	Early resumption	Late resumption
Locking Compression Plate (LCP)	75 (100%)	72 (96%)	3 (4%)
Percutaneous Fixation with K-wires	80 (100%)	45 (56.3%)	35 (43.7%)
External Fixation	77 (100%)	25 (32.5%)	52 (67.5%)

Figure 1: Distribution of operated and non-operated patients during the study period



Discussion

Distal radius fractures are the most common fractures of the upper extremity and constitutes of nearly one-sixth of all fractures treated in emergency [5]. Treatment for the fracture of distal radius varies from traditional method of close reduction and immobilization in a plaster cast to less invasive procedures such as External Fixation and Percutaneous Fixation with K-wires and relatively more complex operative maneuvers of the fractured

bone with Locking Compression Plate. Though the conservative management by close reduction is a widely used treatment for fracture distal radius, it has been associated with inadequate fixation and loosening of the reduction [6,7]. Previous studies have observed a high incidence of displacement deformity in plaster cast treatment [8]. External fixation was thus, considered as one of the better treatment option [2]. Better restoration of normal wrist anatomy can be achieved by external fixation

[9]. The procedure of external fixation is often accompanied with percutaneous fixation with K-wires to maintain the reduction of articular fragments. However, these are frequently associated with pin-track infections, loss of reduction, complex regional pain syndrome and stiffness of joints [10,11]. Open reduction and plate fixation as a treatment for fracture distal radius has gained popularity over the years. This surgical technique involves either a volar or a dorsal incision. A combined volar and dorsal approach has also been used in the treatment of fracture distal radius depending on the extent of displacement and comminution of fracture [1]. In cases of fracture of distal radius, open reduction and internal fixation with volar T-plate radius locking and unlocking in adults is shown to restore articular congruity and restore excellent wrist function [5]. Open reduction and plate fixation is often considered as the treatment of choice for fracture of distal radius especially in comminuted fractures and intra-articular involvement [12,13].

Our observations based on the comparative analysis of different procedures for the treatment of distal radius fractures in the present study, suggest that clinical appearance of the wrist joint was remarkably better due to restoration of wrist anatomy in patients treated with Locking Compression Plate. Clinical outcome in regard to clinical appearance of the wrist joint was similar in patients treated with Percutaneous Fixation with K-wires and External Fixation. In the present study, treatment with Locking Compression Plate showed excellent results with regard to the early restoration of wrist function and

movements of the wrist joint that was related to the early resumption of routine activities. Treatment with Percutaneous Fixation with K-wires showed a moderate result while maximum delay in restoration of wrist joint function was noted for patients treated by External Fixation. Our study findings thus are in support of the views presented in earlier studies [1] that open reduction and plate fixation is a better treatment for distal radius fractures than external fixation and percutaneous fixation. Contrary to our observations, a study by Kreder et al. [14] observed that indirect reduction and percutaneous fixation were associated with a better functional outcome than with open reduction and internal fixation. Differences in the treatment outcome between different treatment modalities in various studies can be attributed to the differences in extent of fractures with articular surface involvement included in the studies and based on techniques applied in treatment.

Conclusions

The present study concludes that Locking Compression Plate is better treatment option for fracture of distal radius than the percutaneous fixation, and external fixation methods. Our observations are based on the clinical appearance of the wrist at discharge, restoration of normal movements of the wrist joint and resumption of normal activities. Better treatment outcome with Locking Compression Plate can be ascribed to proper reduction and rigid fixation, and early mobilization following this procedure and to the absence of pin track infections and post-operative immobilizations.

References

1. Leung F, Tu YK, Chew WY, Chow SP. Comparison of external and percutaneous pin fixation with plate fixation for intra-articular distal radial fractures. A randomized study. *J Bone Joint Surg Am* 2008;90(1):16-22.
2. Moroni A, Vannini F, Faldini C, Pegreff F, Giannini S. Cast vs external fixation: a comparative study in elderly osteoporotic distal radial fracture patients. *Scand J Surg*. 2004;93(1):64-7.
3. Lozano-Calderón SA, Doornberg JN, Ring D. Retrospective Comparison of Percutaneous Fixation and Volar Internal Fixation of Distal Radius Fractures. *Hand* 2008;3:102–110.
4. Handoll HH, Madhok R. Surgical interventions for treating distal radial fractures in adults. *Cochrane Database Syst Rev* 2003;(3):CD003209.
5. Bohra AK, Vijayvergiya SC, Malav R, Jhanwar P. A prospective comparative study of operative treatment of distal radius fracture by using locking and non-locking volar T- plate. *JPBMS* 2012;20 (14).
6. Weber SC, Szabo RM. Severely comminuted distal radial fracture as an unsolved problem: complications associated with external fixation and pins and plaster techniques. *J Hand Surg Am*. 1986;11(2):157-65.
7. Leung KS, Shen WY, Tsang HK, Chiu KH, Leung PC, Hung LK. An effective treatment of comminuted fractures of the distal radius. *J Hand Surg Am*. 1990;15:11–17.
8. Schmalholz A. External skeletal fixation versus cement fixation in the treatment of redislocated Colles' fracture. *Clin Orthop Relat Res* 1990;254:236–241.
9. McQueen MM, Michie M, Court-Brown CM. Hand and wrist function after external fixation of unstable distal radial fractures. *Clin Orthop Relat Res* 1992;285:200–204.
10. Clyburn TA. Dynamic external fixation for comminuted intra-articular fractures of the distal end of the radius. *J Bone Joint Surg Am*. 1987;69:248-54.
11. Edwards GS Jr. Intra-articular fractures of the distal part of the radius treated with the small AO external fixator. *J Bone Joint Surg Am*. 1991;73:1241-50.
12. Jupiter JB. Complex articular fracture of the distal radius classification and management. *J Am Acad Orthop Surg* 1997; 5:119-29.
13. Trumble TE, Culp RW, Hanel DP, Geissler WB, Berger RA. Intra-articular fractures of the distal aspect of the radius. *J Bone Joint Surg Am* 1998; 80:582-600.
14. Kreder HJ, Hanel DP, Agel J, McKee M, Schemitsch EH, Trumble TE, Stephen D. Indirect reduction and percutaneous fixation versus open reduction and internal fixation for displaced intra-articular fractures of the distal radius: a randomised, controlled trial. *J Bone Joint Surg Br*. 2005;87:829-836.

Date of submission: 16 September 2013

Date of Provisional acceptance: 27 September 2013

Date of Final acceptance: 20 October 2013

Date of Publication: 04 December 2013

Source of support: Nil; Conflict of Interest: Nil